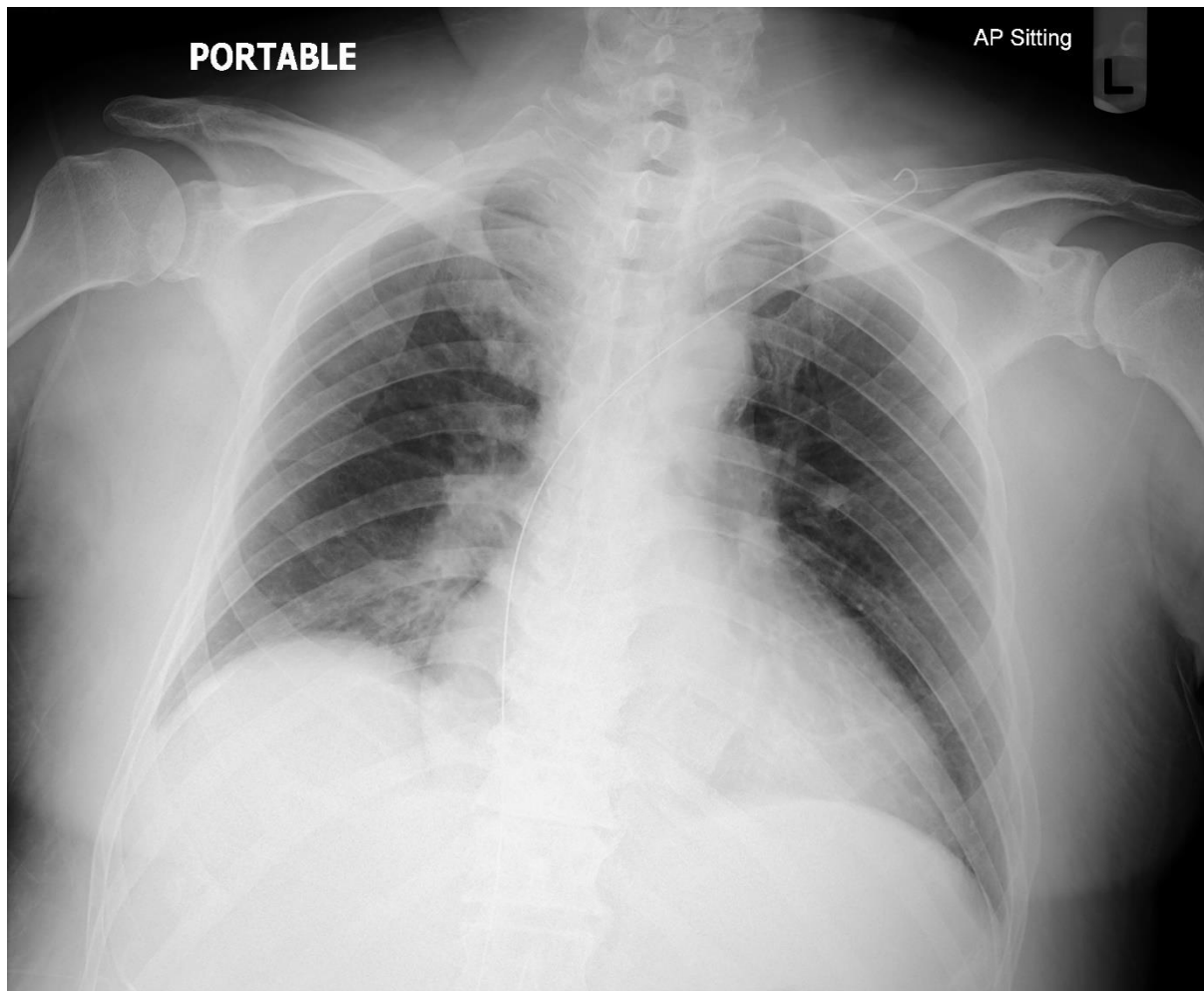




The Hong Kong College of Anaesthesiologists
Final Fellowship Examinations
Paper II - Radiology
25 April 2022 (Monday)
Online

Question 1

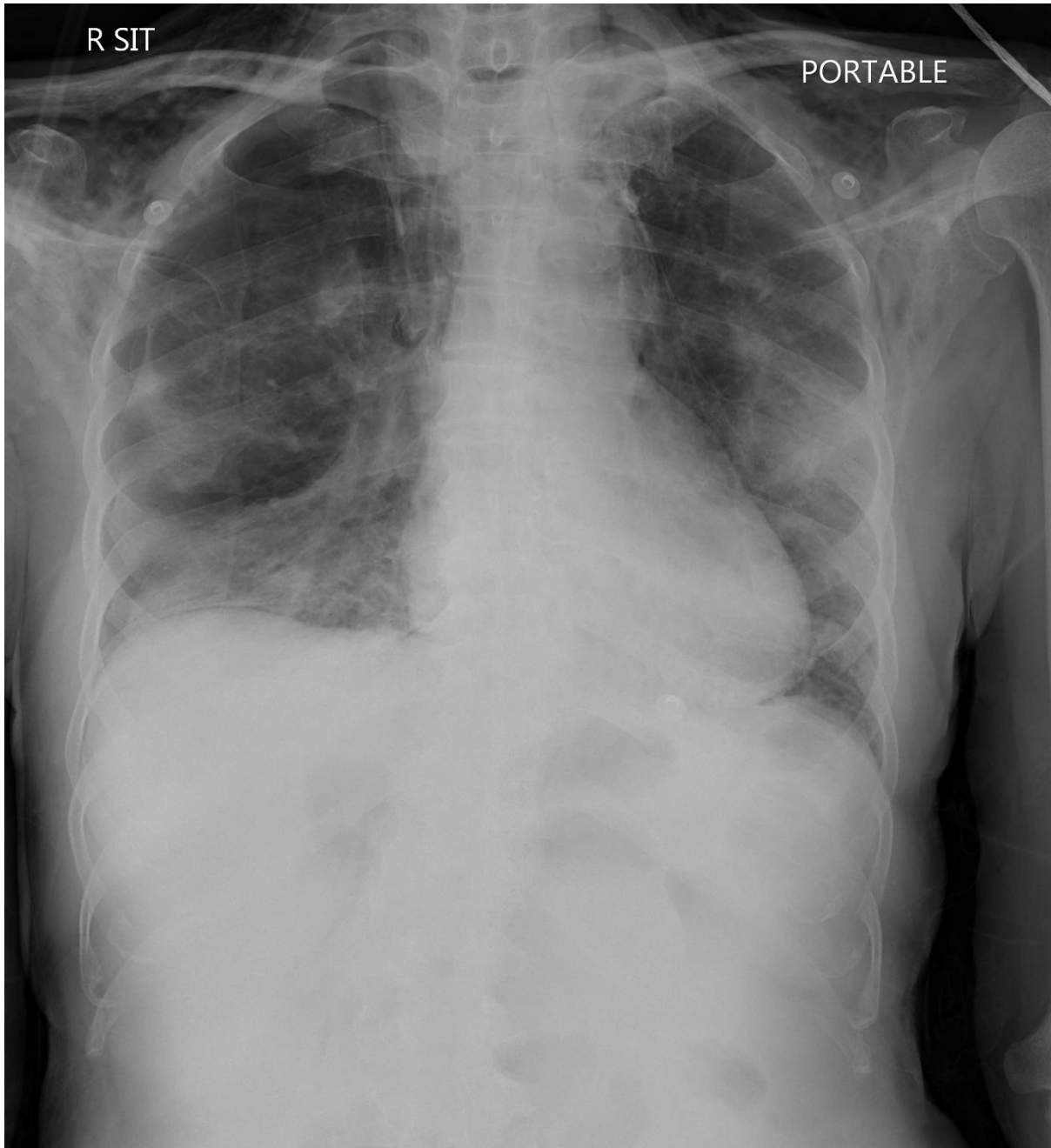
A 65-year-old man recovered from urosepsis with multi-organ failure after receiving broad spectrum antibiotics, vasopressor and renal replacement therapy.



List **TWO** radiological abnormalities (2 marks)

Question 2

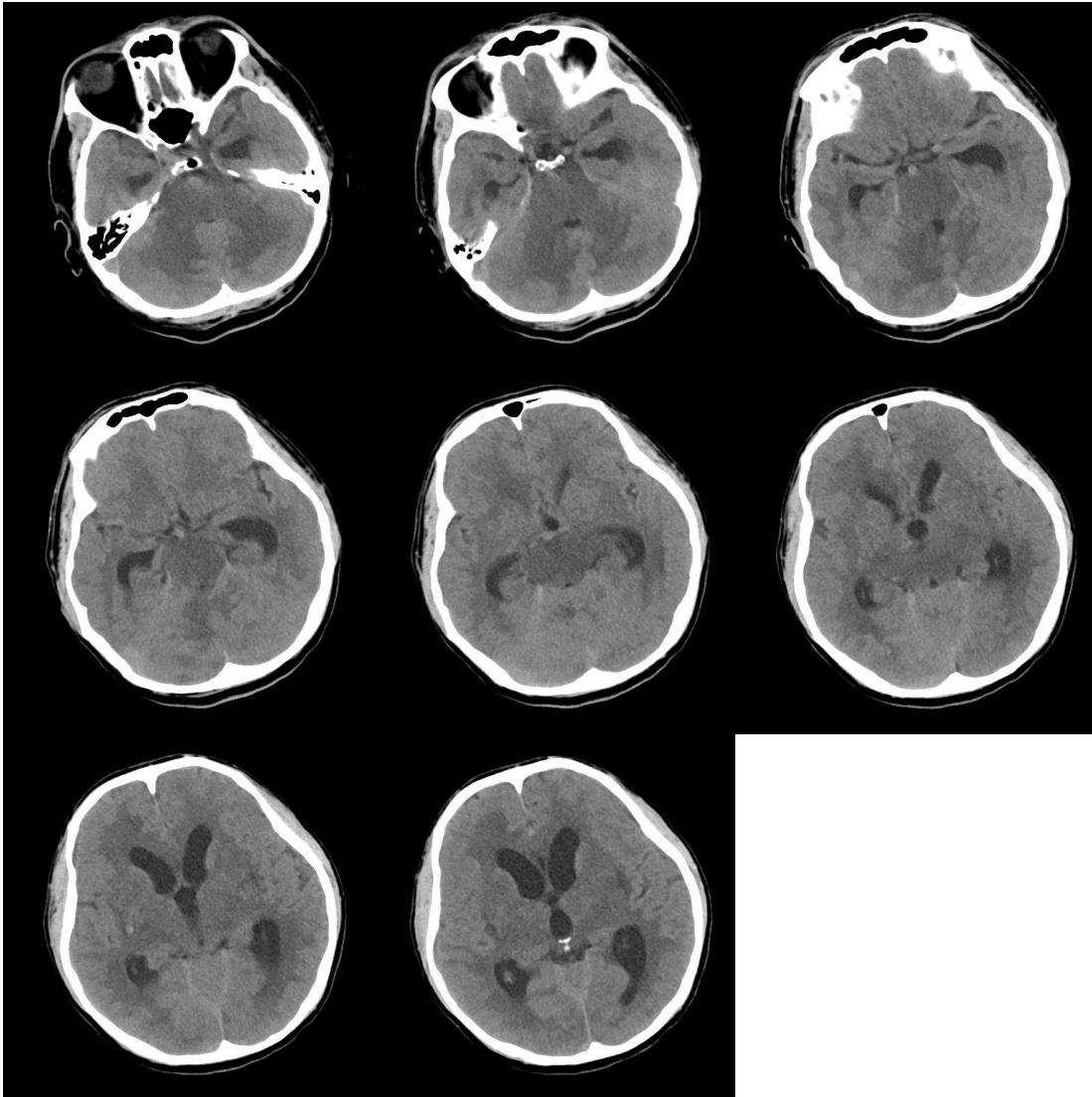
A 70-year-old man stayed in ICU for 10 days because of COVID-19 pneumonitis.



List **FOUR** radiological abnormalities (4 marks)

Question 3

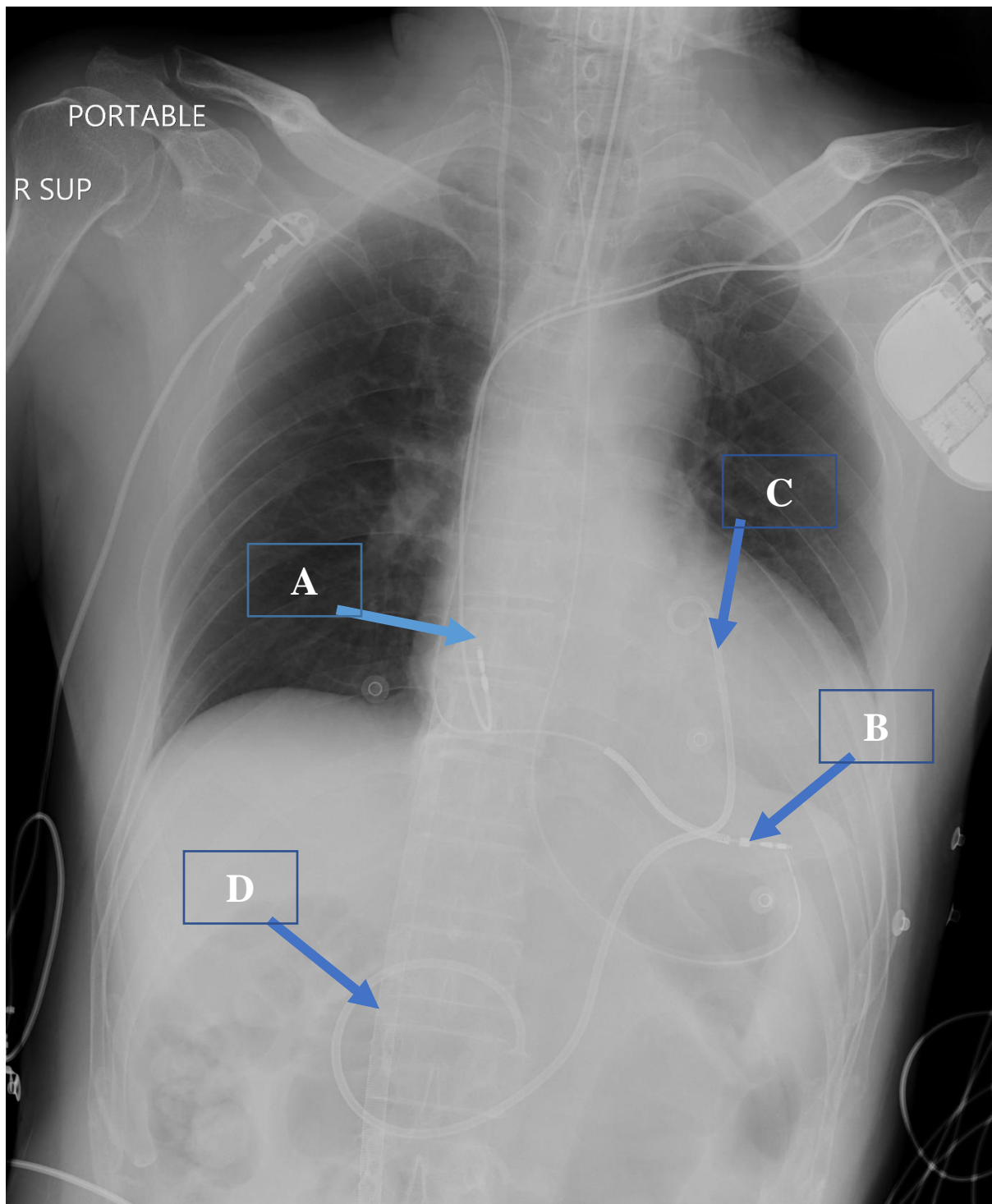
A 55-year-old man was noted to have acute confusion.



List **THREE** radiological abnormalities (3 marks)

Question 4

A 68-year-old man, known to have cardiomyopathy, had finished a prolonged electrophysiological study under general anaesthesia.



Identify the devices (4 marks)

- A: _____
- B: _____

- C: _____
- D: _____

---- End of Paper ----